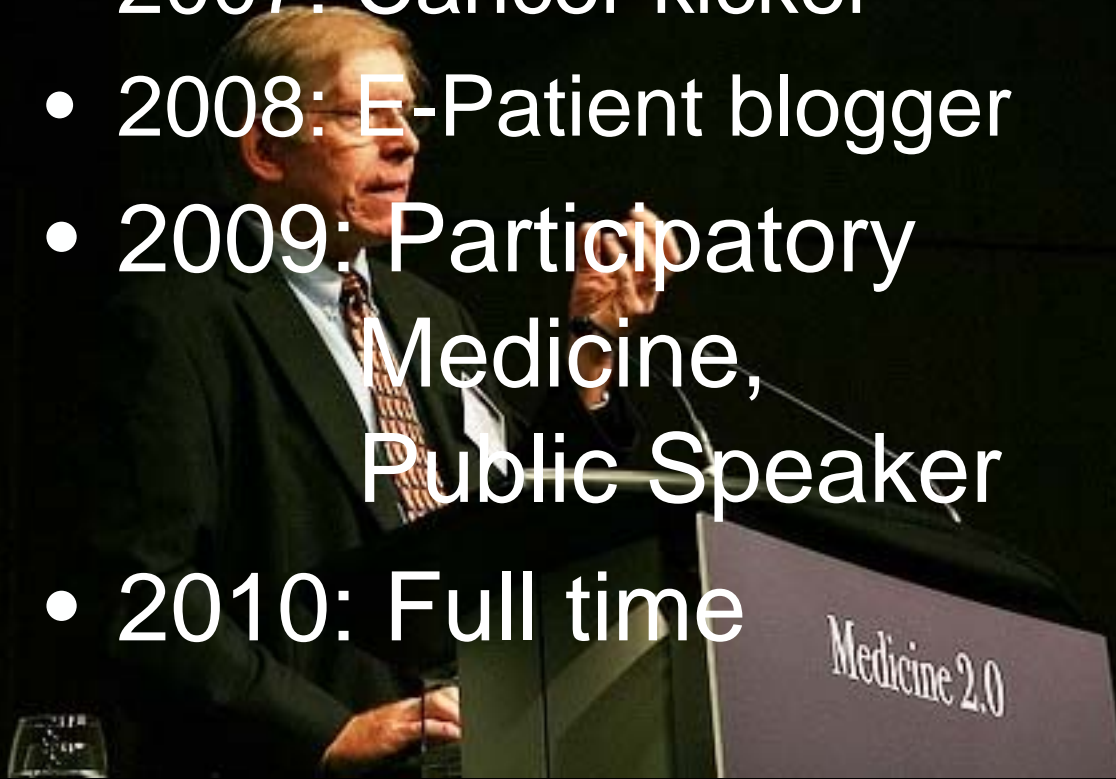

How I came to be here today

- High tech marketing
- Data geek; tech trends; automation
- 2007: Cancer kicker
- 2008: E-Patient blogger
- 2009: Participatory Medicine, Public Speaker
- 2010: Full time





e-patients.net
because health professionals can't do it alone



Doc Tom said,

“e-Patients are

↑
e-Patients.net founder
Equipped
Tom Herguson MD

1944-2006

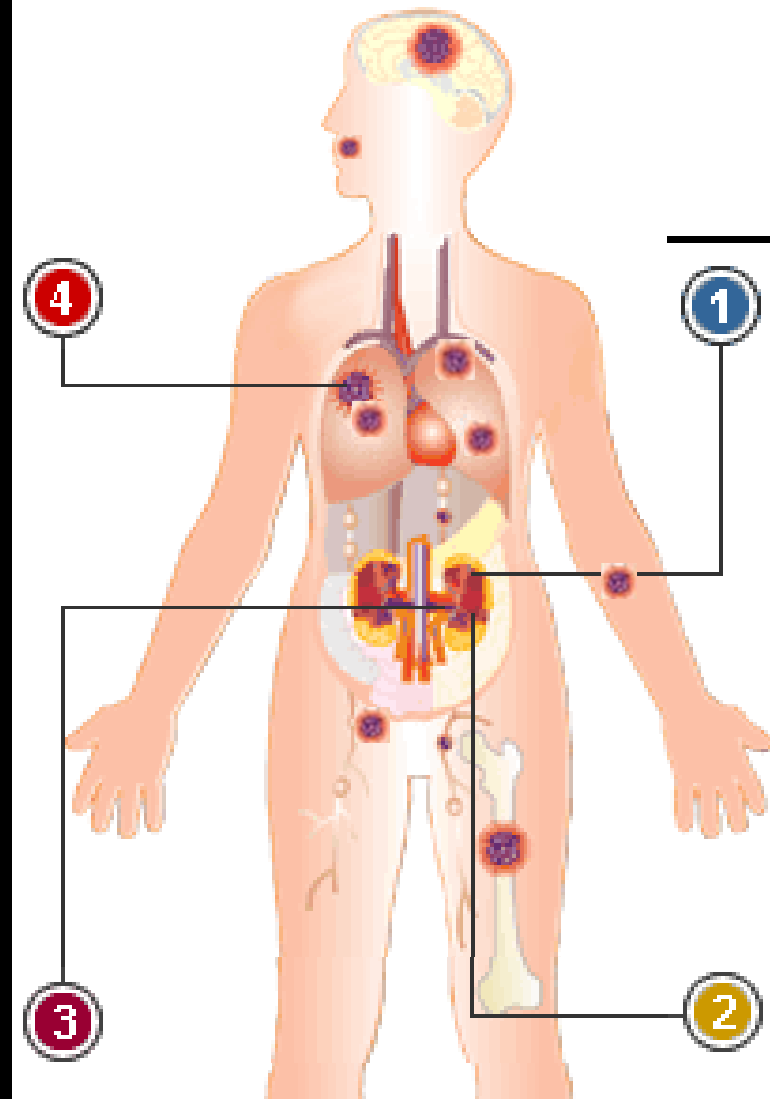
Engaged

Empowered

Enabled”

Classic Stage IV, Grade 4 Renal Cell Carcinoma

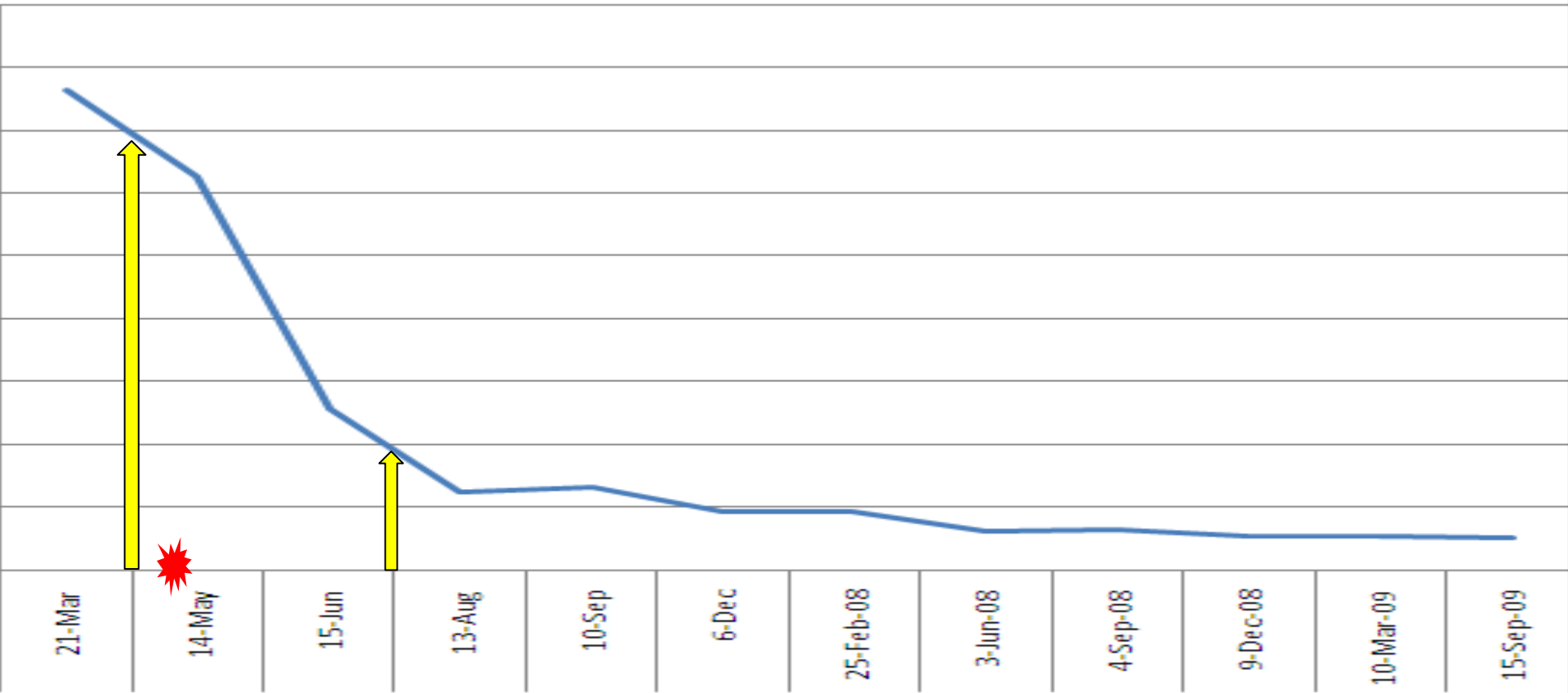
Illustration on
the drug company's
web site



**Median Survival:
24 weeks**

Booyea!

E	F	G	H	I	J	K	L	M	N	O	P	Q	R
21-Mar	APRIL	14-May	15-Jun	JULY	13-Aug	10-Sep	6-Dec	25-Feb-08	3-Jun-08	4-Sep-08	9-Dec-08	10-Mar-09	15-Sep-09
CT	R	CT	CT	R	CT	CT	CT	CT	CT	CT	CT	CT	CT
43x39	O	37x35	29x23	O	22x13	21x13	18x11	20x12	17x9	17x9	17x8	17x8	17x7
41x33	U	42x32	20x18	U	15x15	17x15	14x12	13x13	13x10	13x11	11x10	11x10	11x10
24x22	N	14x11	14x11	N	8x8	stable	8x7	6x8	6x4	5x5	5x5	5x5	6x5
20x13	D	24x14	12x9	D	10x5	stable	7x6	5x2	0x0	0x0	0x0	0x0	0x0
38.18	1	31.29	12.89	2	6.25	6.6	4.64	4.67	3.07	3.21	2.71	2.71	2.59
Reduction since March 07		18%	66%		84%	83%	88%	88%	92%	92%	93%	93%	93%
Reduction since June:					52%	49%	64%	64%	76%	75%	79%	79%	80%



Lesson:

Unmanaged data quality

produces trainwrecks

Follow-up bone check					
10/29/07	189.0	MALIG NEOPL KIDNEY	Orthopedics Spl	A	Orthopedic
10/29/07	198.5	SECONDARY MALIG NEO BONE	Orthopedics Spl	A	Orthopedic
10/29/07	733.15	PATHOL FX OTH PART FEMUR	Orthopedics Spl	A	Orthopedic
10/29/07	V04.81	VACCINATION - INFLUENZA	Orthopedics Spl	A	Orthopedic
10/29/07	V10.52	HX OF KIDNEY MALIGNANCY	Orthopedics Spl	A	Orthopedic
10/29/07	V54.89	OTHER ORTHO AFTERCARE	Orthopedics Spl	A	Orthopedic
Neuro visit - checking to make sure there was no impact on the brain					
11/6/07	780.93	MEMORY LOSS	Behavioral Neur	G	Orthopedic
My first quarterly CT scan for follow-up after completion of treatment					
12/6/07	189.0	MALIG NEOPL KIDNEY	Radiology Cat S	M	Hem/Onc
12/6/07	441.9	AORTIC ANEURYSM NOS	Radiology Cat S	M	Hem/Onc
12/6/07	518.89	NONRHEUM TRICUSP VAL DIS	Radiology Cat S	M	Hem/Onc
12/6/07	560.2	VOLVULUS OF INTESTINE	Radiology Cat S	M	Hem/Onc
12/6/07	721.3	LUMBOSACRAL SPONDYLOSIS	Radiology Cat S	M	Hem/Onc
Pre-surgery cardiac tests to assess whether I could handle the Interl					
3/12/07	401.9	HYPERTENSION NOS	Cardi	M	Hem/Onc
3/12/07	794.30	ABN CARDIOVASC STUDY NOS	Cardi	M	Hem/Onc
Infusion to treat the bone metastasis:					
3/19/07	189.0	MALIG NEOPL KIDNEY	Hem/ Onc Clinic	A	Orthopedic
3/19/07	198.5	SECONDARY MALIG NEO BONE	Hem/ Onc Clinic	A	Orthopedic
3/19/07	424.2	NONRHEUM TRICUSP VAL DIS	Hem/ Onc Clinic	A	Orthopedic
3/19/07	V10.52	HX OF KIDNEY MALIGNANCY	Hem/ Onc Clinic	A	Orthopedic
3/19/07	V58.12	ENC ANTINPLSTC IMMUNORX	Hem/ Onc Clinic	A	Orthopedic
This was when the tumor erupted from my tongue. We didn't know what it was, yet.					
3/21/07	189.0	MALIG NEOPL KIDNEY	Health Care Assoc	I	Internal Med
3/21/07	198.89	SECONDARY MALIG NEO NEC	Health Care Assoc	I	Internal Med
3/21/07	518.89	OTHER LUNG DISEASE NEC	Health Care Assoc	I	Internal Med
3/21/07	529.0	GLOSSITIS	Health Care Assoc	I	Internal Med
3/21/07	729.9	SOFT TISSUE DIS NEC/NOS	Health Care Assoc	I	Internal Med
3/21/07	733.90	BONE & CARTILAGE DIS NOS	Health Care Assoc	I	Internal Med
3/21/07	786.6	CHEST SWELLING/MASS/LUMP	Health Care Assoc	I	Internal Med

Daniel Z. Sands:
Radiologist's report now reads "The heart, great vessels and pericardium are unremarkable." Should not say aneurysm.

Daniel Z. Sands:
Volvulus is a life-threatening kink in the bowel. No volvulus was reported on the CT.

Daniel Z. Sands:
This came from his orthopedist? A) that's unlikely, and b) he never had tricuspid valve disease

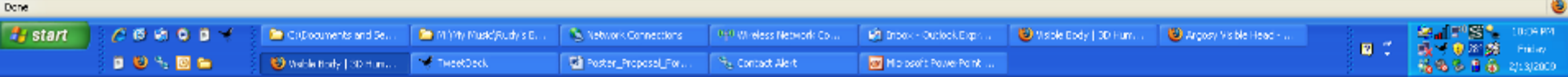
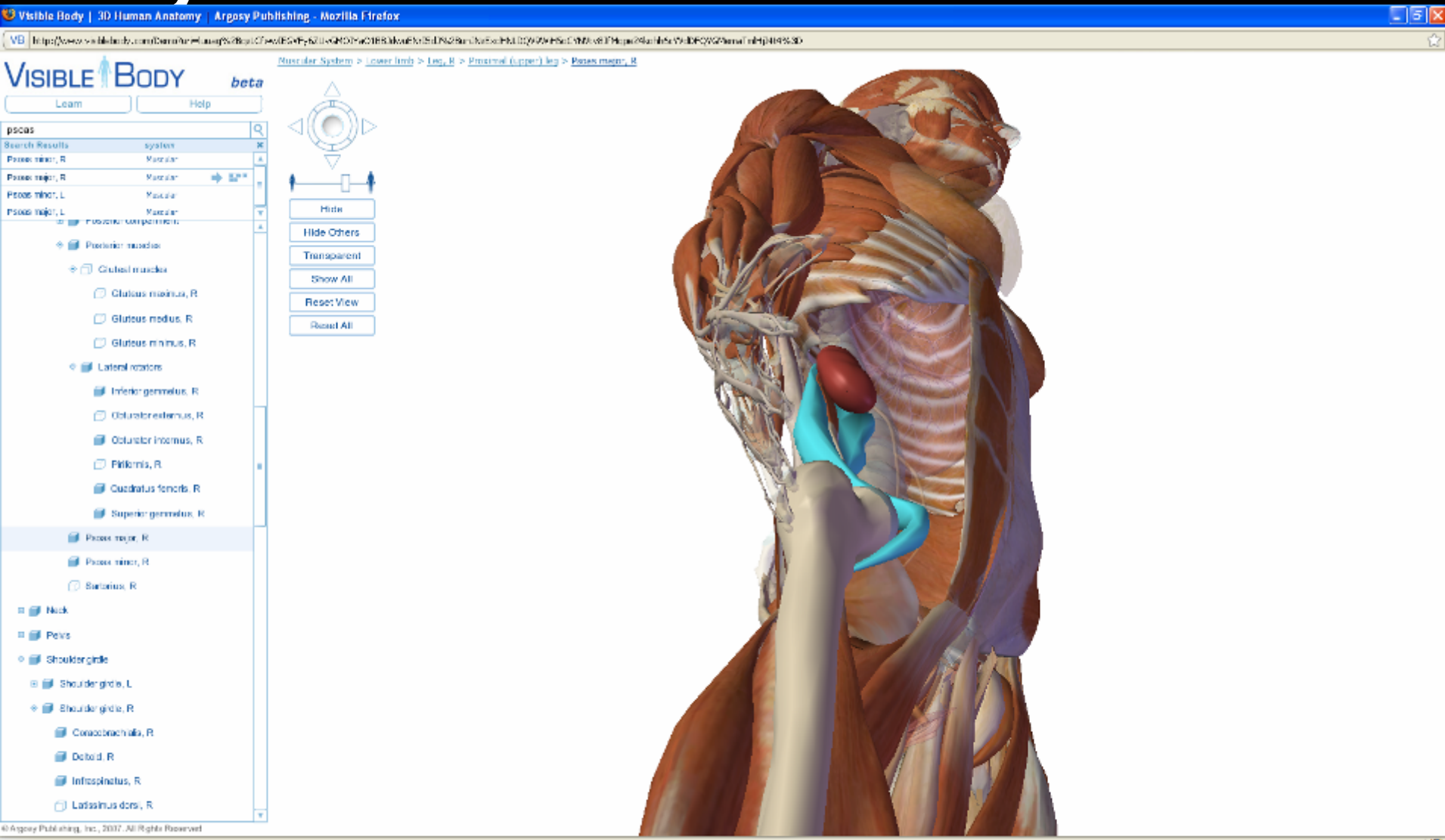
Daniel Z. Sands:
No glossitis, but did have a tongue tumor.
Dave: Glossitis is an inflamed tongue (the whole tongue), not a growth on the tongue.

Daniel Z. Sands:
Not sure what this is.
Dave: It's a diagnosis of bone & cartilage disease - rather odd for a tongue problem!

Data quality risks:

- Physician errors
- Clerical errors
- "Tasty delicious baloney" (upcoding)

Why not “Google Earth for my body”?



When handhelds are included, the digital divide disappears.

- Cell phones leapfrog drinking water



Mammography quiz

You know the following about local women:

21%

- Probability of BC (prevalence) = 1%
- If a woman has BC, probability of testing positive (sensitivity) = 90%
- If a woman does not have BC, probability that she tests positive anyway (false-positive rate) = 2%

of doctors

got it right.

A woman tests positive. She wants to know the odds she has BC. What's the best answer?

A. ~81%

B. "Out of 10 positive mammograms, 9 do have BC"

C. "Out of 10 positive mammograms, 1 has BC"

D. ~1%

2.8 e-Patient Years in Pictures...

December 2006

October 2007

May 2009



September 2009

